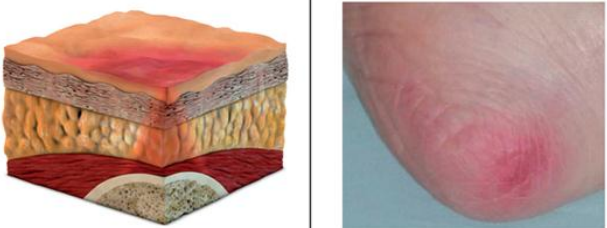

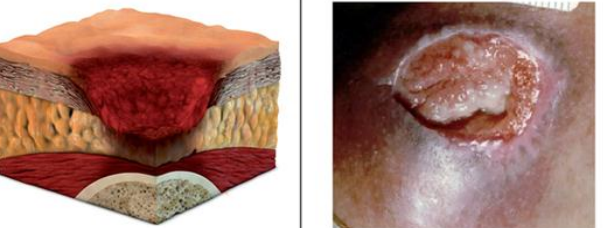


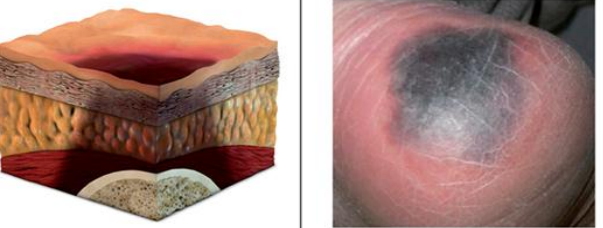


Pressure injury classification system

| Stage I pressure injury: non-blanchable erythema | Stage II pressure injury: partial thickness skin loss | Stage III pressure injury: full thickness skin loss |
|---|---|--|
| <ul style="list-style-type: none"> Intact skin with non-blanchable redness of a localised area usually over a bony prominence. Darkly pigmented skin may not have visible blanching; its colour may differ from the surrounding area. The area may be painful, firm, soft, warmer or cooler compared to adjacent tissue. May be difficult to detect in individuals with dark skin tones. May indicate "at risk" persons (a heralding sign of risk). | <ul style="list-style-type: none"> Partial thickness loss of dermis presenting as a shallow, open wound with a red-pink wound bed, without slough. May also present as an intact or open/ruptured serum-filled blister. Presents as a shiny or dry, shallow ulcer without slough or bruising (NB bruising indicates suspected deep tissue injury). Stage II PI should not be used to describe skin tears, tape burns, perineal dermatitis, maceration or excoriation. | <ul style="list-style-type: none"> Full thickness tissue loss. Subcutaneous fat may be visible but bone, tendon or muscle are not exposed. Slough may be present but does not obscure the depth of tissue loss. May include undermining and tunnelling. The depth of a stage III PI varies by anatomical location. The bridge of the nose, ear, occiput and malleolus do not have subcutaneous tissue and stage III PIs can be shallow. In contrast, areas of significant adiposity can develop extremely deep stage III PIs. Bone or tendon is not visible or directly palpable. |
|  |  |  |
| Stage IV pressure injury: full thickness tissue loss | Unstageable pressure injury: depth unknown | Suspected deep tissue injury: depth unknown |
| <ul style="list-style-type: none"> Full thickness tissue loss with exposed bone, tendon or muscle. Slough or eschar may be present on some parts of the wound bed. The depth of a stage IV pressure injury varies by anatomical location. The bridge of the nose, ear, occiput and malleolus do not have subcutaneous tissue and these PIs can be shallow. Stage IV PIs can extend into muscle and/or supporting structures (e.g. fascia, tendon or joint capsule) making osteomyelitis possible. Exposed bone or tendon is visible or directly palpable. | <ul style="list-style-type: none"> Full thickness tissue loss in which the base of the PI is covered by slough (yellow, tan, grey, green or brown) and/or eschar (tan, brown or black) in the PI bed. Until enough slough/eschar is removed to expose the base of the PI, the true depth, and therefore the stage, cannot be determined. Stable (dry, adherent, intact without erythema or fluctuance) eschar on the heels serves as the body's natural biological cover and should not be removed. | <ul style="list-style-type: none"> Purple or maroon localised area or discoloured, intact skin or blood-filled blister due to damage of underlying soft tissue from pressure and/or shear. The area may be preceded by tissue that is painful, firm, mushy, boggy, warmer or cooler as compared to adjacent tissue. Deep tissue injury may be difficult to detect in individuals with dark skin tone. Evolution may include a thin blister over a dark wound bed. The PI may further involve and become covered by thin eschar. Evolution may be rapid, exposing additional layers of tissue even with optimal treatment. |
|  |  |  |

All 3D graphics designed by Jarrad Giffos, Gear Interactive, <http://www.gearinteractive.com.au>

Photos stage, I,IV, unstageable and suspected deep tissue injury courtesy C. Young, Launceston General Hospital. Photos stage II and III courtesy K. Carville, Silver Chain. Used with permission.